SYNOPTIK-FONDENS 2022 ÅRSSEMINAR

STED
Mogens Dahl Koncertsal
Snorresgade 22
2300 København

6 November

Stamcelleterapi til aldersrelateret makuladegeneration (AMD)

Professor THOMAS CORYDON

Department of Biomedicine
Aarhus University
DENMARK

Department of Ophthalmology
Aarhus University Hospital
Denmark

AARHUS UNIVERSITY

Stamcelleterapi til aldersrelateret makuladegeneration (AMD)

- Kan stamcelleterapi standse eller reetablere synstab efter RPE-celle og photorecepter-død?
- Hvad viser den seneste forskning, og kan man producere nok stamceller til de mange AMD-patienter?
- Forskel på hESC og hiPSC
- Er vi i mål med RPE-stamcelleterapi?

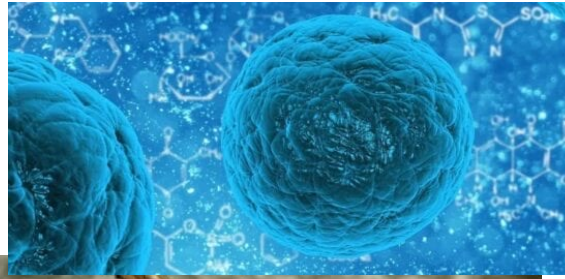

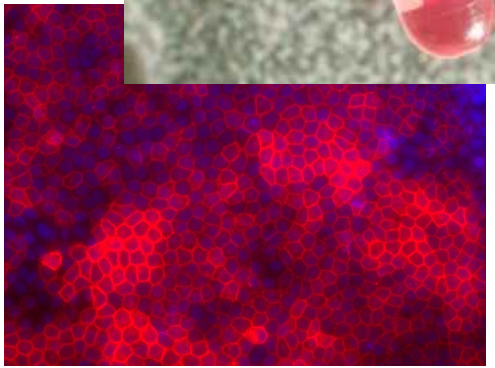

Age-related Macular Degeneration (AMD)

– a multifactorial slowly progressing disease, affecting approx. 50% of the elderly population

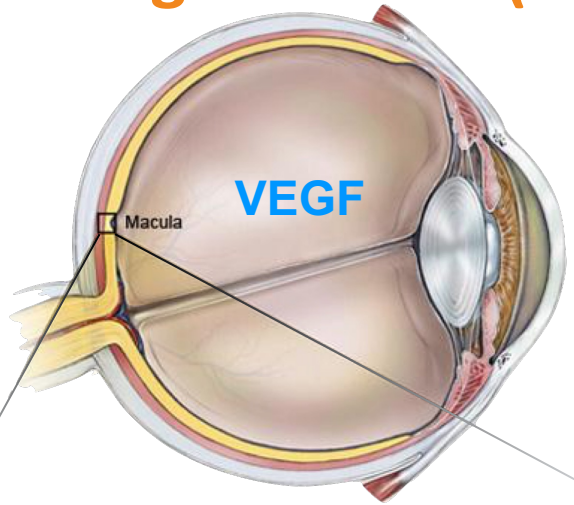

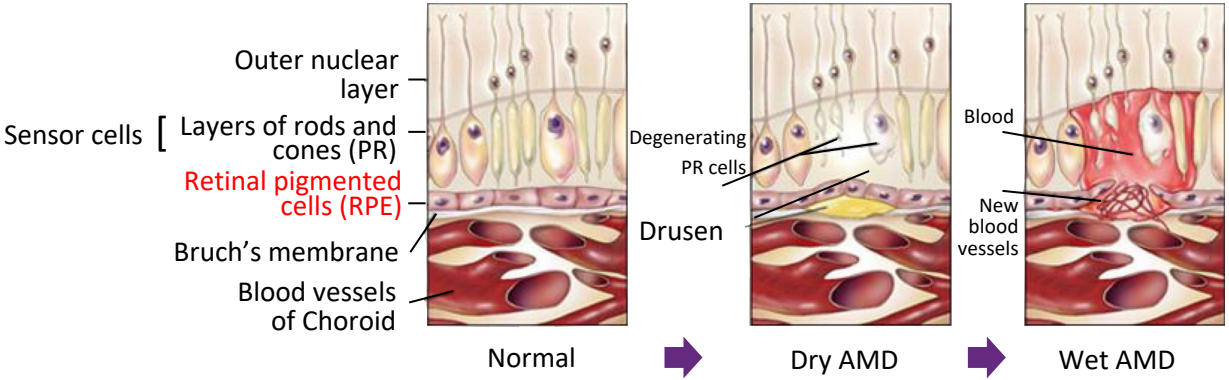

Current treatment of wAMD:

Reoccurring intravitreal injections of VEGF inhibitors

Living with AMD:

2020: 196 mill

2040: 288 mill

17% of 45–85 years old adults will suffer loss of vision or blindness due to AMD

Bright Focus Foundation

Age-related Macular Degeneration (AMD)

Dysfunktion eller død af RPE forårsager photoreceptor-tab og permanent tab af det centrale syn

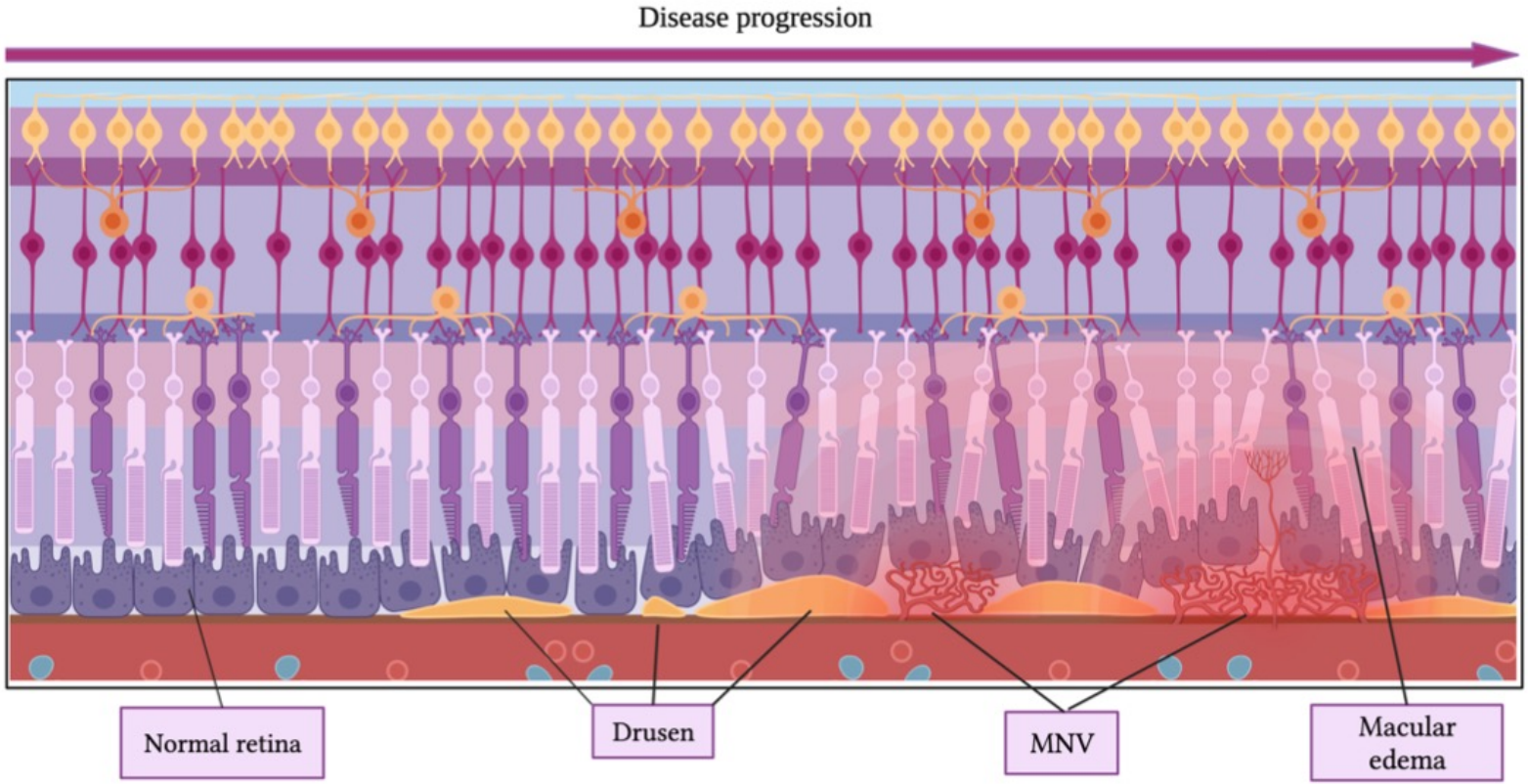

Created with BioRender.com

VEGF antagonists used in clinical practice (wAMD)

	Bevacizumab (Avastin)	Ranibizumab (Lucentis)	Aflibercept (Eylea)	Brolucizumab (Beovu)
	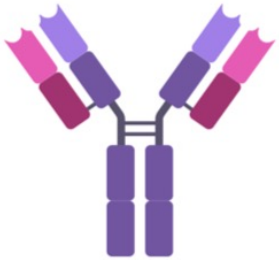		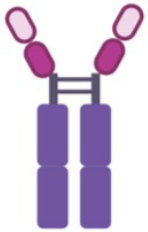	
Format	Full monoclonal antibody	Antibody fragment	VEGRF1/2 recombinant fusion protein	Single-chain antibody fragment
Molecular mass	149 kD	48 kD	115 kD	26 kD
Target(s)	All VEGF-A isofom	All VEGF-A isofom	All VEGF-A, VEGF-B, and P1GF isoforms	All VEGF-A isofom

Created with BioRender.com

Not always effective, is not curative, and involves multiple injections into the eye. Currently NO treatment available for dry AMD that improves vision

Stem Cell Therapy

Creating **ES cells**

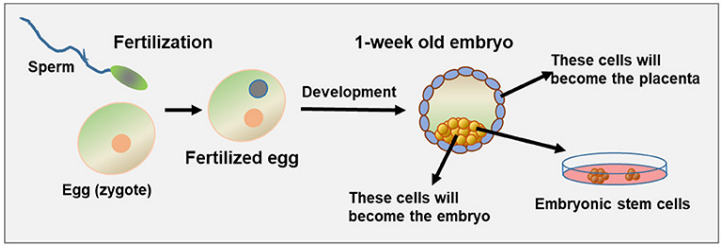

Meshorer E (2020). Front. Young Minds. 8:32. doi: 10.3389/frym.2020.00032

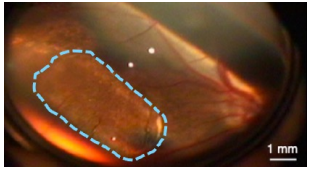

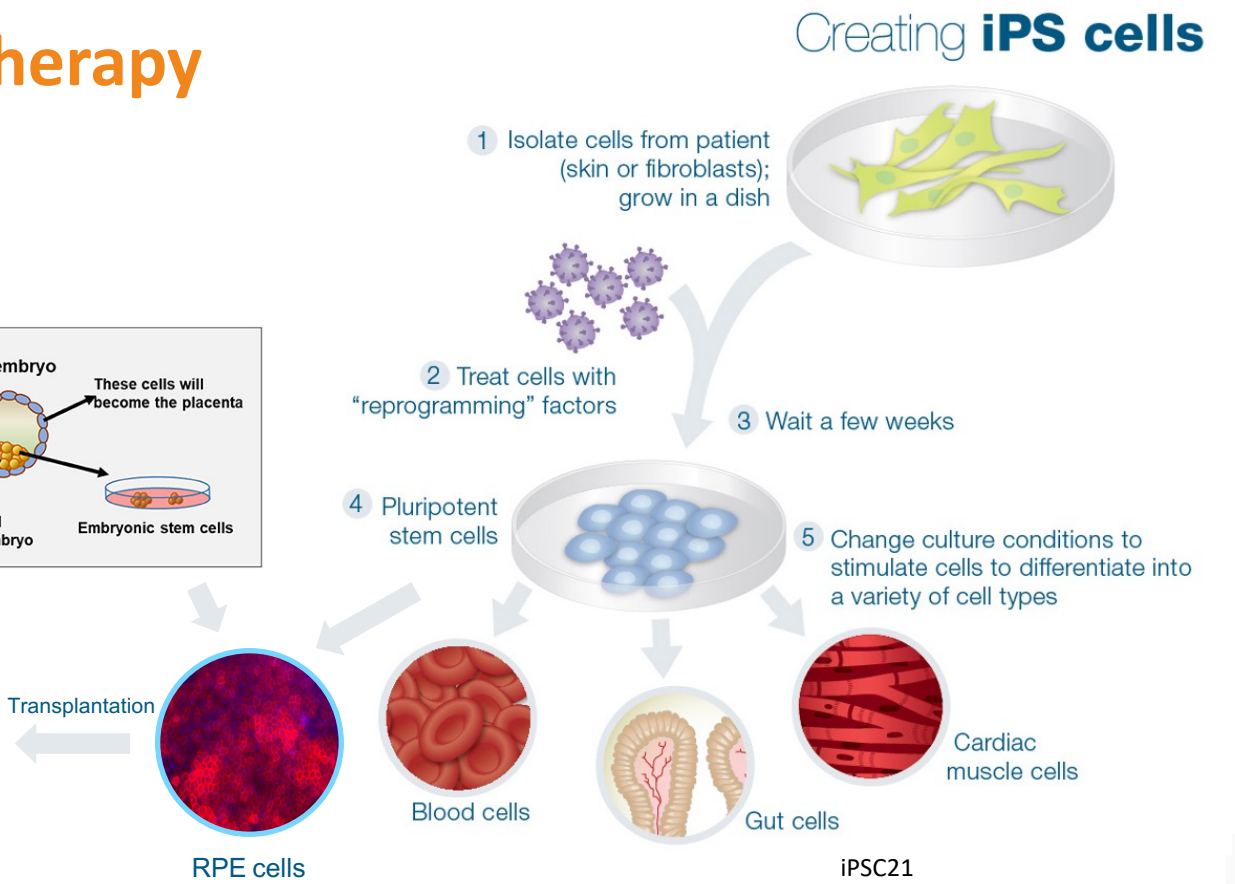

Retinal pigment epithelium

- Multifunctional monolayer
- Required for the health and function of neighbouring photoreceptor cells in the retina

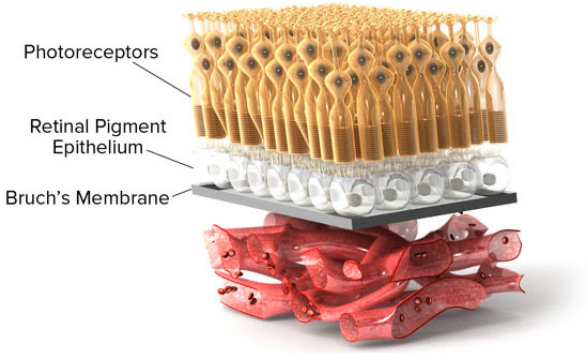

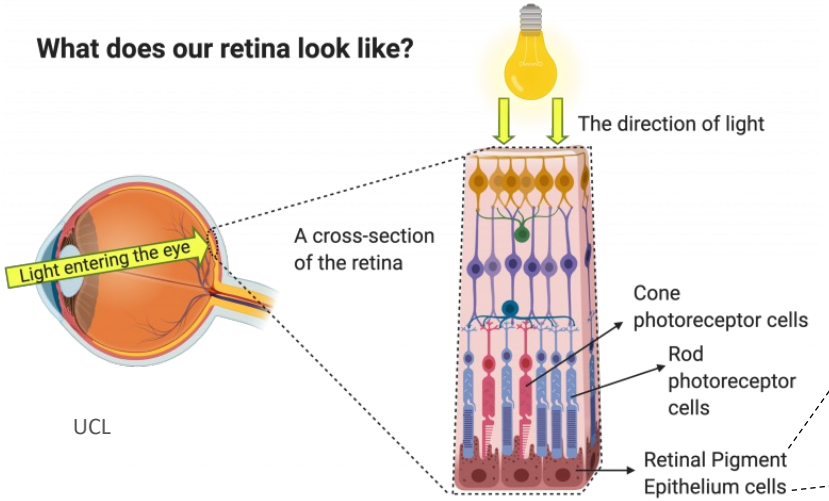

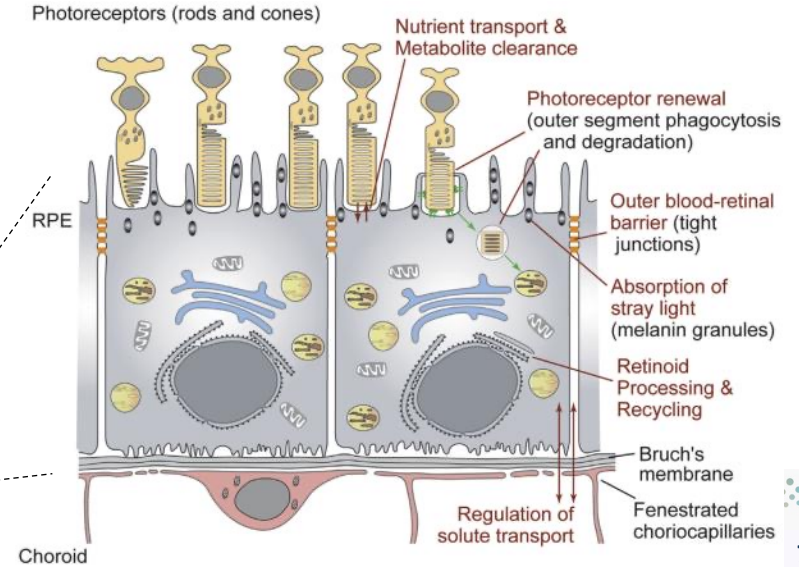

Europe PMC

RPE

- Polaritet
- PR fornyelse
- Transport af nærringsstoffer
- Nedbrydning af metabolitter
- Retionid “recycling”
- Regulering af opløste stoffer

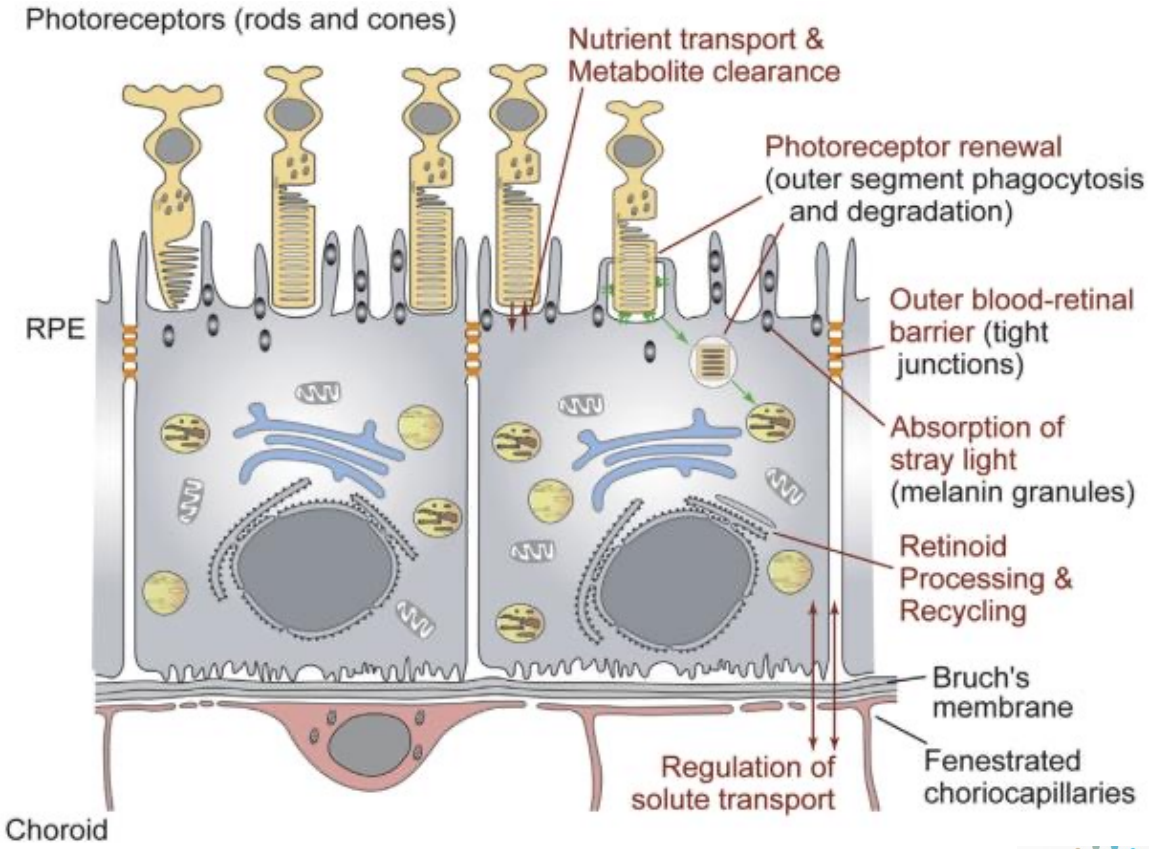

Europe PMC

Retinal pigment epithelium





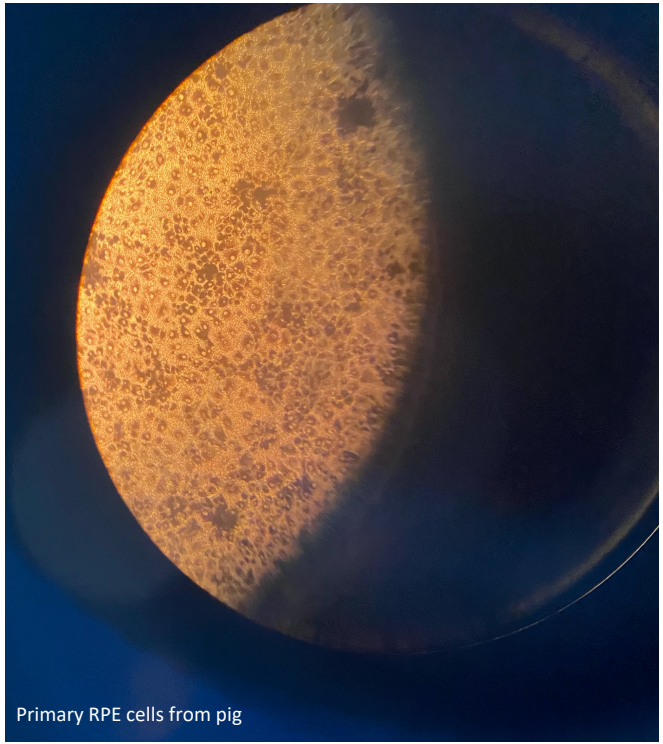

Primary RPE cells from pig

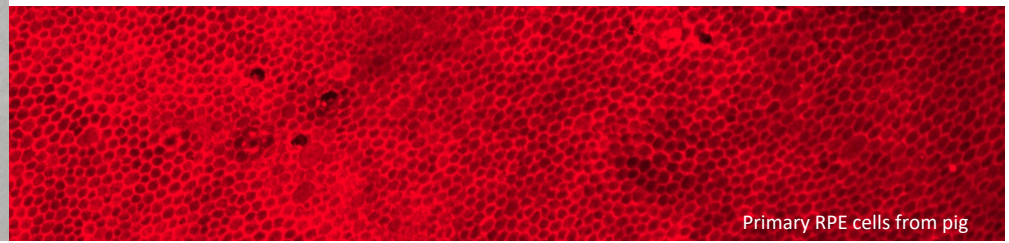

Primary RPE cells from pig

RPE transplantation in animal model with defect RPEs

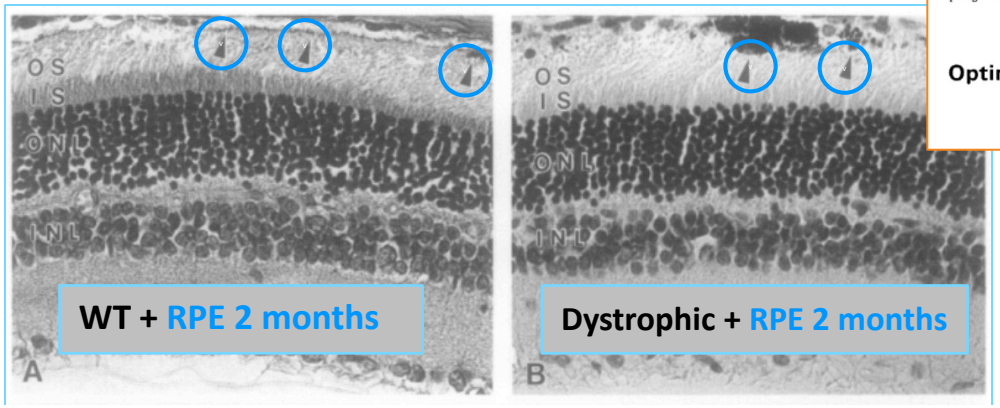

Exp. Eye Res. (1991) 52, 669–679

Optimal Conditions for Long-term Photoreceptor Cell Rescue in RCS Rats: The Necessity for Healthy RPE Transplants

LINXI LI AND JAMES E. TURNER

Transplantation of stem cell derived RPEs in AMD pt

nature biotechnology

Phase 1 clinical study of an embryonic stem cell–derived retinal pigment epithelium patch in age-related macular degeneration

Lyndon da Cruz[1–4], Kate Fynes[1], Odysseas Georgiadis[1–3], Julie Kerby[5,6], Yvonne H Luo[1–3], Ahmad Ahmado[1], Amanda Vernon[7], Julie T Daniels[7], Britta Nommiste[1], Shazeen M Hasan[1], Sakina B Gooljar[1], Amanda-Jayne F Carr[1], Anthony Vugler[1], Conor M Ramsden[1,3], Magda Bictash[5], Mike Fenster[5], Juliette Steer[5], Tricia Harbinson[5], Anna Wilbrey[5], Adnan Tufail[2,3], Gang Feng[5], Mark Whitlock[5], Anthony G Robson[2,3], Graham E Holder[2,3], Mandeep S Sagoo[2,3], Peter T Loudon[5], Paul Whiting[5,8] & Peter J Coffey[1,2,9]

Cell-on membrane concept (improvement in vision in 2 out of 2 Pt wAMD)

SCIENCE TRANSLATIONAL MEDICINE | RESEARCH ARTICLE

RETINAL DISEASE

A bioengineered retinal pigment epithelial monolayer for advanced, dry age-related macular degeneration

Amir H. Kashani,[1]* Jane S. Lebkowski,[2] Firas M. Rahhal,[3] Robert L. Avery,[4] Hani Salehi-Had,[5] Wei Dang,[6] Chih-Min Lin,[6] Debbie Mitra,[1] Danhong Zhu,[7] Biju B. Thomas,[1] Sherry T. Hikita,[8] Britney O. Pennington,[8] Lincoln V. Johnson,[2,8] Dennis O. Clegg,[8] David R. Hinton,[1,7] Mark S. Humayun[1,9]*

The NEW ENGLAND JOURNAL of MEDICINE

BRIEF REPORT

Autologous Induced Stem-Cell–Derived Retinal Cells for Macular Degeneration

M. Mandai, A. Watanabe, Y. Kurimoto, Y. Hirami, C. Morinaga, T. Daimon, M. Fujihara, H. Akimaru, N. Sakai, Y. Shibata, M. Terada, Y. Nomiya, S. Tanishima, M. Nakamura, H. Kamao, S. Sugita, A. Onishi, T. Ito, K. Fujita, S. Kawamata, M.J. Go, C. Shinohara, K. Hata, M. Sawada, M. Yamamoto, S. Ohta, Y. Ohara, K. Yoshida, J. Kuwahara, Y. Kitano, N. Amano, M. Umekage, F. Kitaoka, A. Tanaka, C. Okada, N. Takasu, S. Ogawa, S. Yamanaka, and M. Takahashi

These clinical trials demonstrate proof–of–concept for stem cell therapy to treat AMD

Transplantation of stem cell derived RPEs in AMD pt

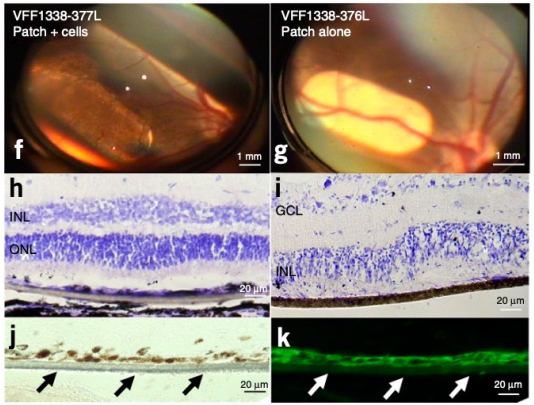

dysfunction and loss of retinal pigment
prising a fully differentiated, human
ent membrane. We delivered the patch,
n each of two patients with severe exudative
tion of subjects with improved best-corrected
e RPE patch by biomicroscopy and optical
coherence tomography, and a visual acuity gain of 29 and 21 letters in the two patients, respectively, over 12 months. Only local immunosuppression was used long-term. We also present the preclinical surgical, cell safety and tumorigenicity studies leading to trial approval. This work supports the feasibility and safety of hESC-RPE patch transplantation as a regenerative strategy for AMD.

Transplantation of stem cell derived RPEs in AMD pt

nature biotechnology

Phase 1 clinical study of an embryonic stem cell–derived retinal pigment epithelium patch in age-related macular degeneration

Lyndon da Cruz[1–5], Kate Fynes[1], Odysseas Georgiadis[1–5], Julie Kerby[5,6], Yvonne H Luo[1–3], Ahmad Ahmado[1], Amanda Vernon[7], Julie T Daniels[7], Britta Nommiste[1], Shazeen M Hasan[1], Sakina B Gooljar[1], Amanda-Jayne F Carr[2], Anthony Vugler[1], Conor M Ramsden[8,3], Magda Bictash[5], Mike Fenster[8], Juliette Steer[8], Tricia Harbinson[8], Anna Wilbrey[9], Adnan Tufail[2,3], Gang Feng[5], Mark Whitlock[5], Anthony G Robson[2,3], Graham E Holder[2,3], Mandeep S Sagoo[2,3], Peter T Loudon[8], Paul Whiting[5,6] & Peter J Coffey[1,2,8]

hESC expansion

VTN-N coating

T25 flasks until confluent

Essential 8 medium

- Appearance and viability
- Karyotype

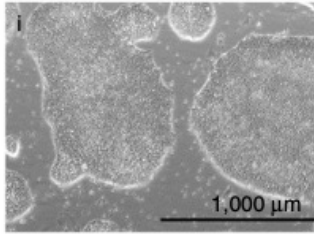

nature biotechnology

Phase 1 clinical study of an embryonic stem cell–derived retinal pigment epithelium patch in age-related macular degeneration

Lyndon da Cruz[1–5], Kate Fynes[1], Odysseas Georgiadis[1–5], Julie Kerby[5,6], Yvonne H Luo[1–3], Ahmad Ahmado[1], Amanda Vernon[7], Julie T Daniels[7], Britta Nommiste[1], Shazeen M Hasan[1], Sakina B Gooljar[1], Amanda-Jayne F Carr[2], Anthony Vugler[1], Conor M Ramsden[8,3], Magda Bictash[5], Mike Fenster[5], Juliette Steer[5], Tricia Harbinson[5], Anna Wilbrey[9], Adnan Tufail[2,3], Gang Feng[5], Mark Whitlock[5], Anthony G Robson[2,3], Graham E Holder[2,3], Mandeep S Sagoo[2,3], Peter T Loudon[5], Paul Whiting[5,8] & Peter J Coffey[1,2,8]

Characterization

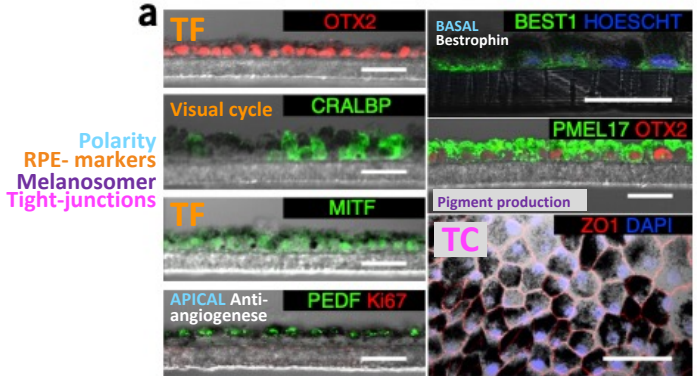

nature biotechnology

Phase 1 clinical study of an embryonic stem cell–derived retinal pigment epithelium patch in age-related macular degeneration

Lyndon da Cruz[1–5], Kate Fynes[1], Odysseas Georgiadis[1–5], Julie Kerby[5,6], Yvonne H Luo[1–3], Ahmad Ahmado[1], Amanda Vernon[7], Julie T Daniels[7], Britta Nommiste[1], Shazeen M Hasan[1], Sakina B Gooljar[1], Amanda-Jayne F Carr[2], Anthony Vugler[1], Conor M Ramsden[1,3], Magda Bictash[5], Mike Fenster[8], Juliette Steer[8], Tricia Harbinson[5], Anna Wilbrey[9], Adnan Tufail[2,3], Gang Feng[5], Mark Whitlock[5], Anthony G Robson[2,3], Graham E Holder[2,3], Mandeep S Sagoo[2,3], Peter T Loudon[5], Paul Whiting[5,6] & Peter J Coffey[1,2,5]

Characterization of RPE patch in mice

Non-injected

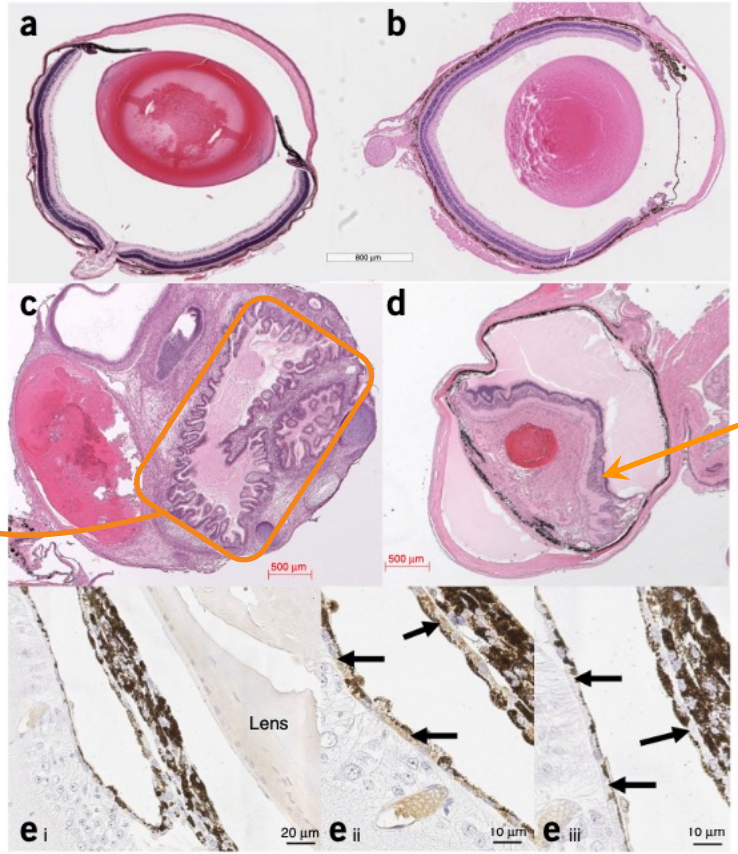

6 weeks old mice injected with hESC-RPE
@ 26 weeks no teratomas

26 weeks old. Injected with undifferiented hESCs. Teratomas

An example of a mesenchymal tumor in an animal injected with undifferentiated hESC

Human mitochondria = hESC-RPEs

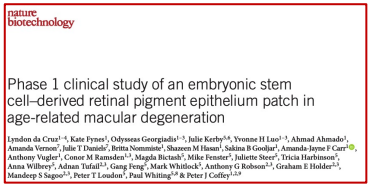
nature biotechnology

Phase 1 clinical study of an embryonic stem cell–derived retinal pigment epithelium patch in age-related macular degeneration

Lyndon da Cruz[1–5], Kate Fynes[1], Odysseas Georgiadis[1–5], Julie Kerby[5,6], Yvonne H Luo[1–3], Ahmad Ahmado[1], Amanda Vernon[7], Julie T Daniels[7], Britta Nommiste[1], Shazeen M Hasan[1], Sakina B Gooljar[1], Amanda-Jayne F Carr[2], Anthony Vugler[1], Conor M Ramsden[8–3], Magda Bictash[5], Mike Fenster[5], Juliette Steer[5], Tricia Harbinson[5], Anna Wilbrey[9], Adnan Tufail[2,3], Gang Feng[5], Mark Whitlock[5], Anthony G Robson[2,3], Graham E Holder[2,3], Mandeep S Sagoo[2,3], Peter T Loudon[5], Paul Whiting[5,8] & Peter J Coffey[1,2,8]

Human-vitronectin-coated polyester membrane

Vitronectin:

BioReagent, suitable for cell culture

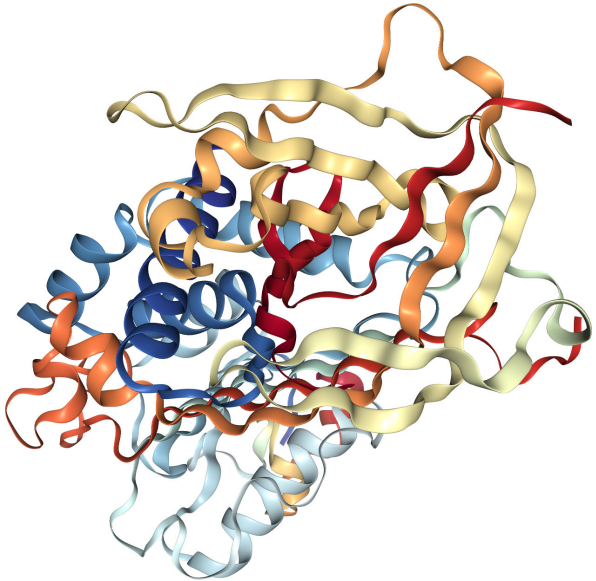

REP monolayer

Polyester membrane

nature biotechnology

Phase 1 clinical study of an embryonic stem cell–derived retinal pigment epithelium patch in age-related macular degeneration

Lyndon da Cruz[1–5], Kate Fynes[1], Odysseas Georgiadis[1–5], Julie Kerby[5,6], Yvonne H Luo[1–3], Ahmad Ahmado[1], Amanda Vernon[7], Julie T Daniels[7], Britta Nommiste[1], Shazeen M Hasan[1], Sakina B Gooljar[1], Amanda-Jayne F Carr[2], Anthony Vugler[1], Conor M Ramsden[1,2], Magda Bictash[5], Mike Fenster[8], Juliette Steer[8], Tricia Harbinson[8], Anna Wilbrey[9], Adnan Tufail[2,3], Gang Feng[5], Mark Whitlock[5], Anthony G Robson[2,3], Graham E Holder[2,3], Mandeep S Sagoo[2,3], Peter T Loudon[8], Paul Whiting[5,9] & Peter J Coffey[1,2,9]

Pig transplantation studies

Retinal detachment and rupture of the lens capsule were observed in 2 out of 40 animals implanted with the patch

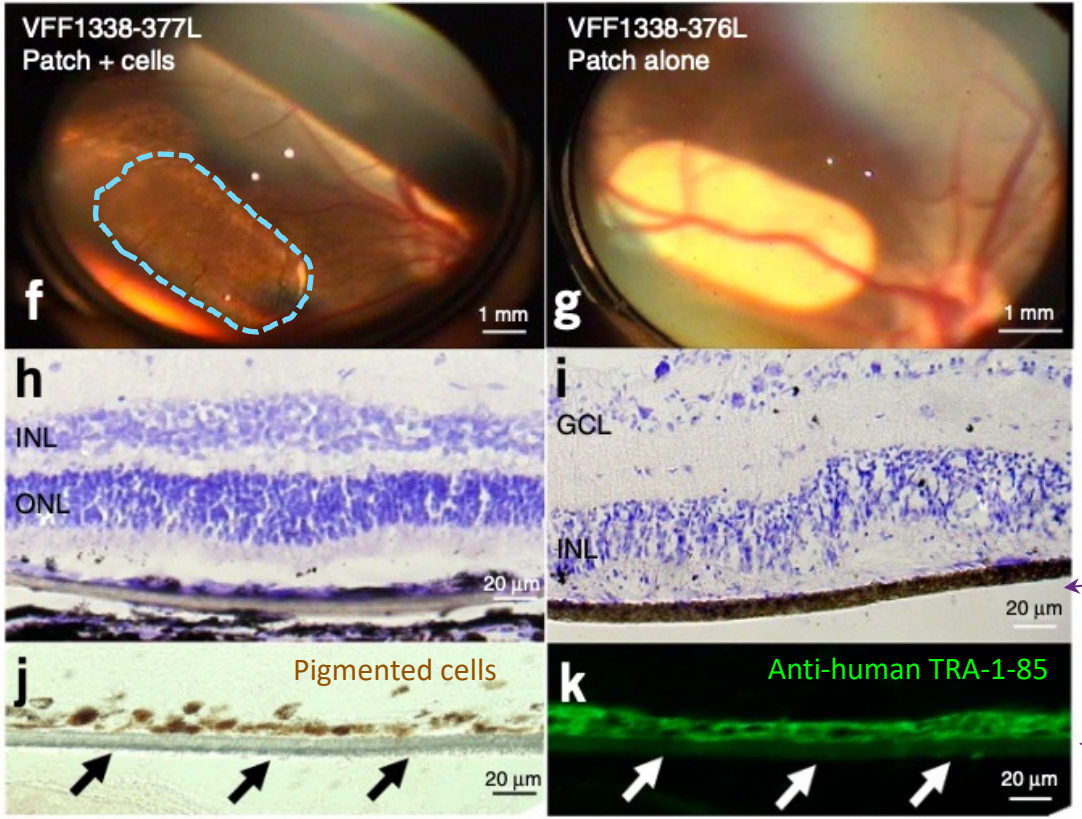

Membrane + cells

Uncoated cell-free membrane

Membrane + cells

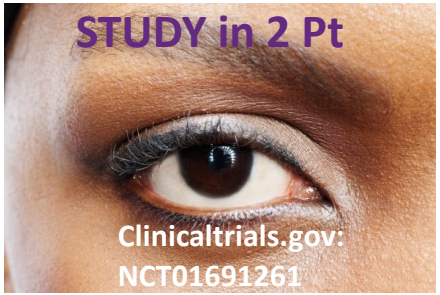

Safety?

Delivery of the RPE monolayer?

Survival of transplanted cells?

Potential efficacy?

e_{iii}: The patches showed uneven autofluorescence, which suggests functioning RPE phagocytosis

nature biotechnology

Phase 1 clinical study of an embryonic stem cell–derived retinal pigment epithelium patch in age-related macular degeneration

Lyndon da Cruz[1–4], Kate Fynes[1], Odysseas Georgiadis[1–5], Julie Kerby[5,6], Yvonne H Luo[1–3], Ahmad Ahmado[1], Amanda Vernon[7], Julie T Daniels[7], Britta Nommiste[1], Shazeen M Hasan[1], Sakina B Gooljar[1], Amanda-Jayne F Carr[2], Anthony Vugler[1], Conor M Ramsden[1,3], Magda Bictash[5], Mike Fenster[8], Juliette Steer[8], Tricia Harbinson[8], Anna Wilbrey[9], Adnan Tufail[2,3], Gang Feng[5], Mark Whitlock[5], Anthony G Robson[2,3], Graham E Holder[2,3], Mandeep S Sagoo[2,3], Peter T Loudon[5], Paul Whiting[5,8] & Peter J Coffey[1,2,8]

Case 1

Sequences of color photographs

Clinicaltrials.gov: NCT01691261
Two patients: Case 1–2

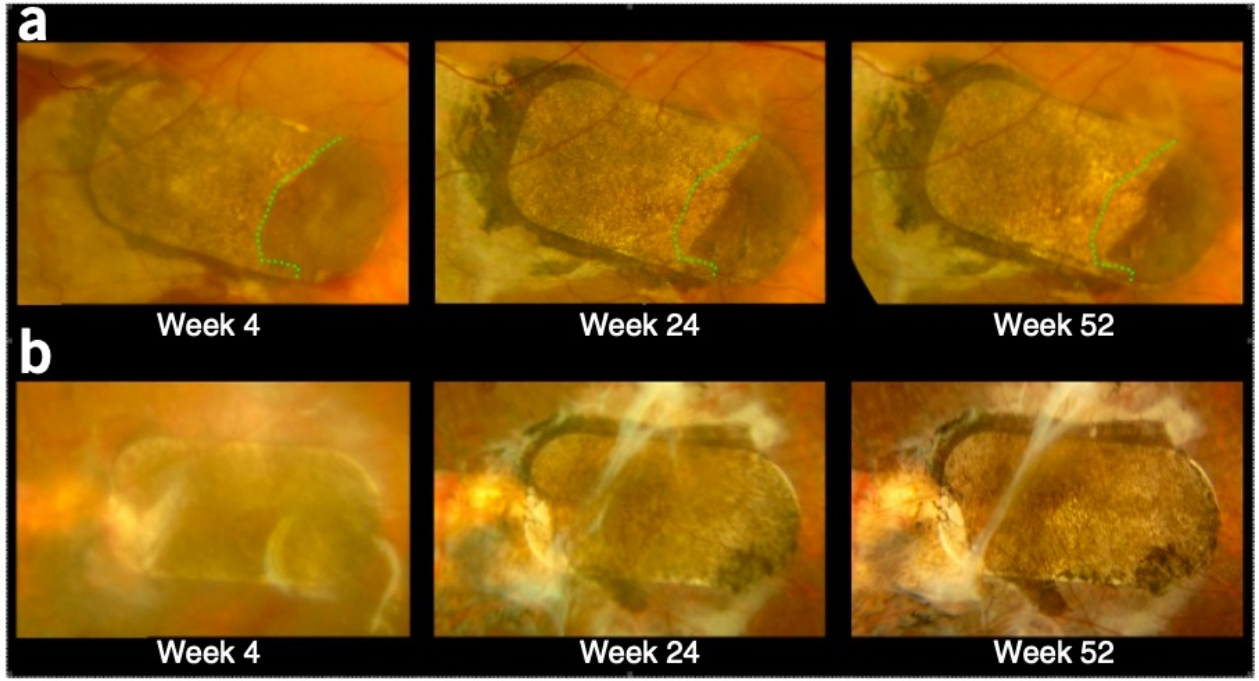

Darker, pigmented areas continuous with the patch, which may represent RPE cell migration off the patch onto adjacent RPE-deficient areas.

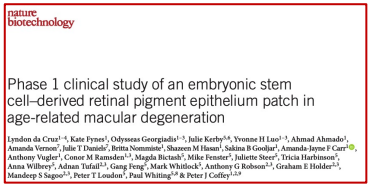
nature biotechnology

Phase 1 clinical study of an embryonic stem cell–derived retinal pigment epithelium patch in age-related macular degeneration

Lyndon da Cruz[1–5], Kate Fynes[1], Odysseas Georgiadis[1–5], Julie Kerby[5,6], Yvonne H Luo[1–3], Ahmad Ahmado[1], Amanda Vernon[7], Julie T Daniels[7], Britta Nommiste[1], Shazeen M Hasan[1], Sakina B Gooljar[1], Amanda-Jayne F Carr[2], Anthony Vugler[1], Conor M Ramsden[1,3], Magda Bictash[5], Mike Fenster[8], Juliette Steer[8], Tricia Harbinson[5], Anna Wilbrey[9], Adnan Tufail[2,3], Gang Feng[5], Mark Whitlock[5], Anthony G Robson[2,3], Graham E Holder[2,3], Mandeep S Sagoo[2,3], Peter T Loudon[8], Paul Whiting[5,6] & Peter J Coffey[1,2,8]

Case 1

Best-Corrected Visual Acuity & Reading Speed

Case 1: 12 mo

Case 2: 12 mo

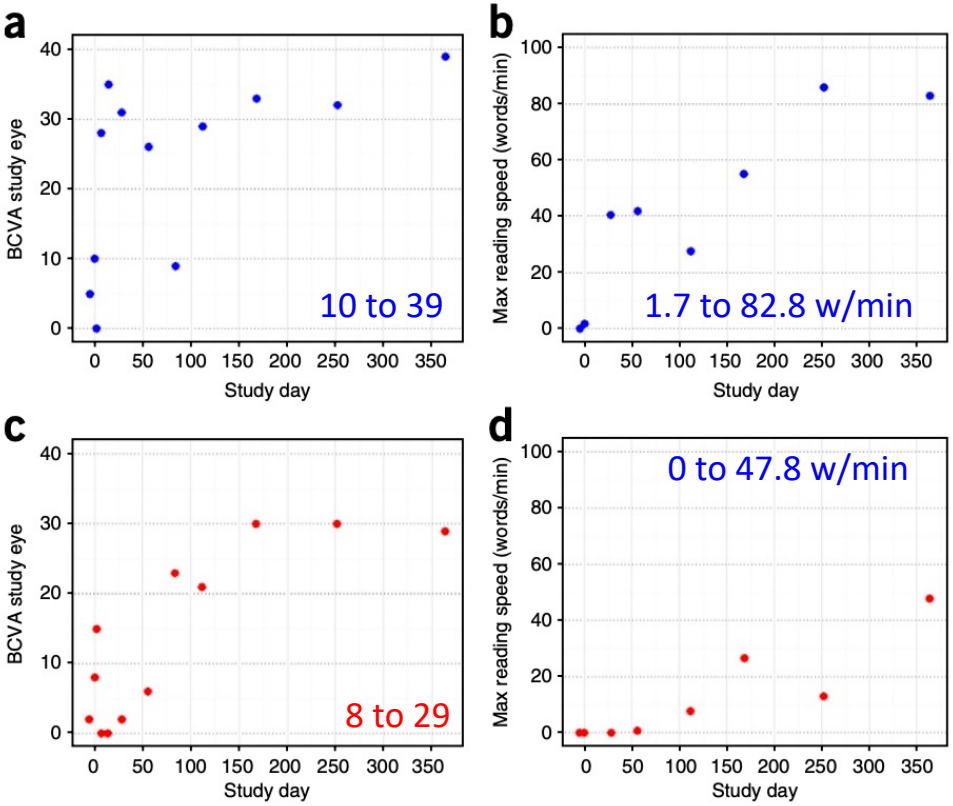

Three serious adverse events:

Exposure to suture

Worsening of diabetes

Retinal detachment

nature biotechnology

Phase 1 clinical study of an embryonic stem cell–derived retinal pigment epithelium patch in age-related macular degeneration

Lyndon da Cruz[1–4], Kate Fynes[1], Odysseas Georgiadis[1–3], Julie Kerby[5,6], Yvonne H Luo[1–3], Ahmad Ahmado[1], Amanda Vernon[7], Julie T Daniels[7], Britta Nommiste[1], Shazeen M Hasan[1], Sakina B Gooljar[1], Amanda-Jayne F Carr[1], Anthony Vugler[1], Conor M Ramsden[1,3], Magda Bictash[5], Mike Fenster[5], Juliette Steer[5], Tricia Harbinson[5], Anna Wilbrey[5], Adnan Tufail[2,3], Gang Feng[5], Mark Whitlock[5], Anthony G Robson[2,3], Graham E Holder[2,3], Mandeep S Sagoo[2,3], Peter T Loudon[5], Paul Whiting[5,8] & Peter J Coffey[1,2,9]

CONCLUSIONS

Engineering, manufacturing, and delivering a clinical-grade hESC-RPE patch, leading to stabilization and improvement of vision for at least 12 months in two subjects with severe vision loss from AMD

SCIENCE TRANSLATIONAL MEDICINE | RESEARCH ARTICLE

RETINAL DISEASE

A bioengineered retinal pigment epithelial monolayer for advanced, dry age-related macular degeneration

Amir H. Kashani,[1]* Jane S. Lebkowski,[2] Firas M. Rahhal,[3] Robert L. Avery,[4] Hani Salehi-Had,[5] Wei Dang,[6] Chih-Min Lin,[6] Debbie Mitra,[1] Danhong Zhu,[7] Biju B. Thomas,[1] Sherry T. Hikita,[8] Britney O. Pennington,[8] Lincoln V. Johnson,[2,8] Dennis O. Clegg,[8] David R. Hinton,[1,7] Mark S. Humayun[1,9]*

Purpose: **To assess the safety and efficacy of a composite subretinal implant in subjects with advanced NNAMD**

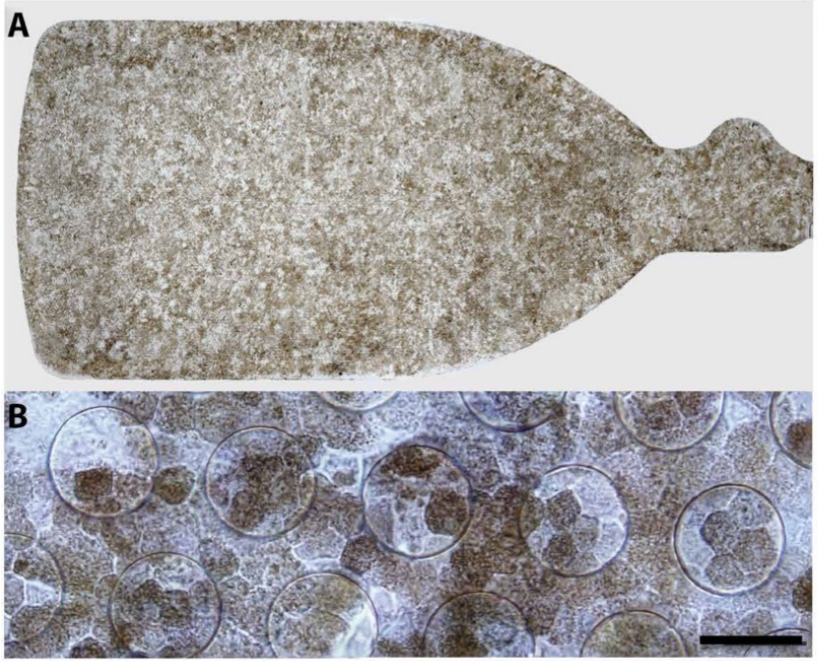

Polarized monolayer of human embryonic stem cell–derived RPE (hESC-RPE) on an ultrathin, synthetic polymer designed to mimic Bruch's membrane

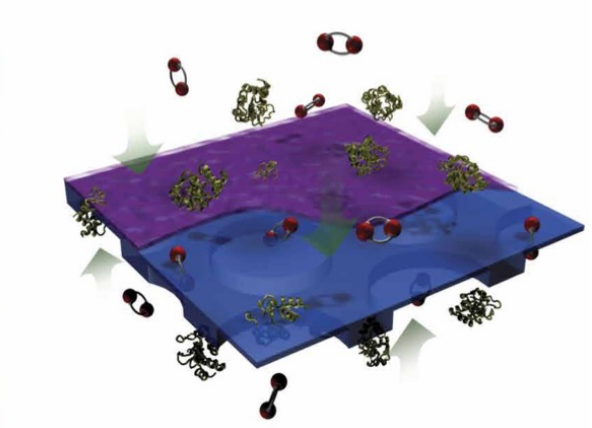

Preoperative and postoperative color fundus photographs

Pt204 Pt125

Pre OP

Post OP

Post OP Annotated

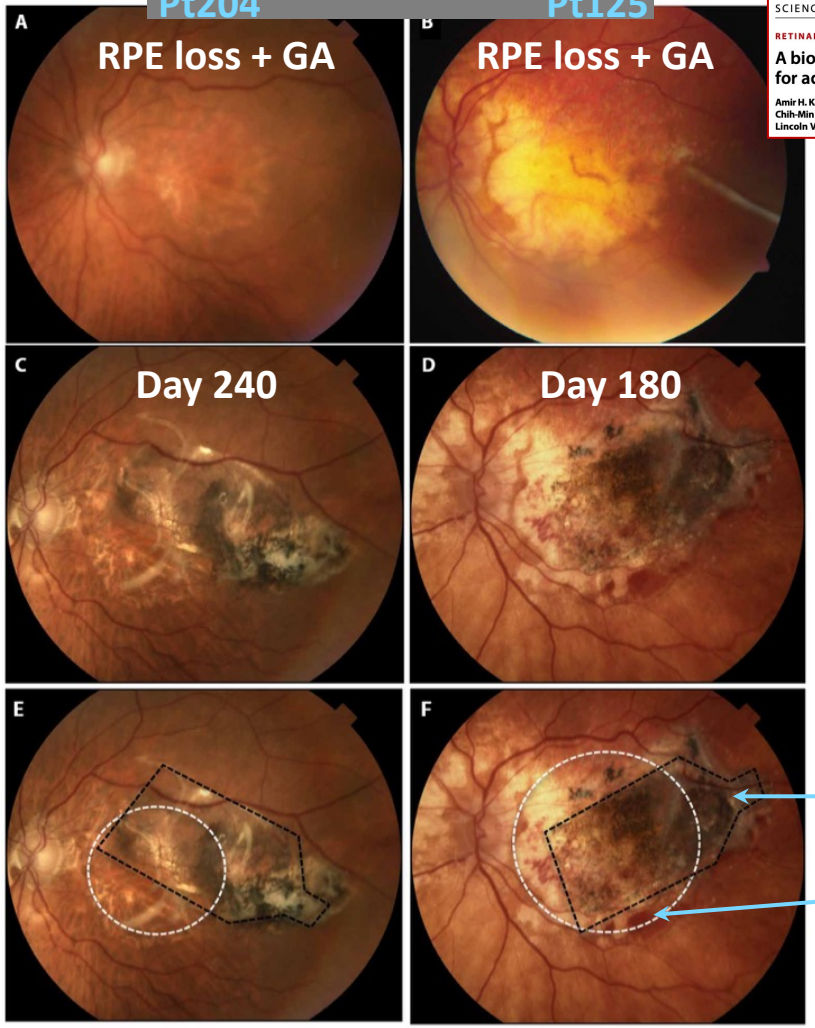

RPE donor cells

GA

SCIENCE TRANSLATIONAL MEDICINE | RESEARCH ARTICLE

RETINAL DISEASE

A bioengineered retinal pigment epithelial monolayer for advanced, dry age-related macular degeneration

Amir H. Kashani,[1,*] Jane S. Lebkowski,[2] Firas M. Rahhal,[3] Robert L. Avery,[4] Hani Salehi-Had,[5] Wei Dang,[6] Chih-Min Lin,[6] Debbie Mitra,[1] Danhong Zhu,[7] Biju B. Thomas,[1] Sherry T. Hikita,[8] Britney O. Pennington,[8] Lincoln V. Johnson,[2,9] Dennis O. Clegg,[8] David R. Hinton,[1,7] Mark S. Humayun[1,9,*]

Visual activity

SCIENCE TRANSLATIONAL MEDICINE | RESEARCH ARTICLE

RETINAL DISEASE

A bioengineered retinal pigment epithelial monolayer for advanced, dry age-related macular degeneration

Amir H. Kashani,[1,*] Jane S. Lebkowski,[2] Firas M. Rahhal,[3] Robert L. Avery,[4] Hani Salehi-Had,[5] Wei Dang,[6] Chih-Min Lin,[6] Debbie Mitra,[1] Danhong Zhu,[7] Biju B. Thomas,[1] Sherry T. Hikita,[8] Britney O. Pennington,[8] Lincoln V. Johnson,[2,8] Dennis O. Clegg,[8] David R. Hinton,[1,7] Mark S. Humayun[1,9*]

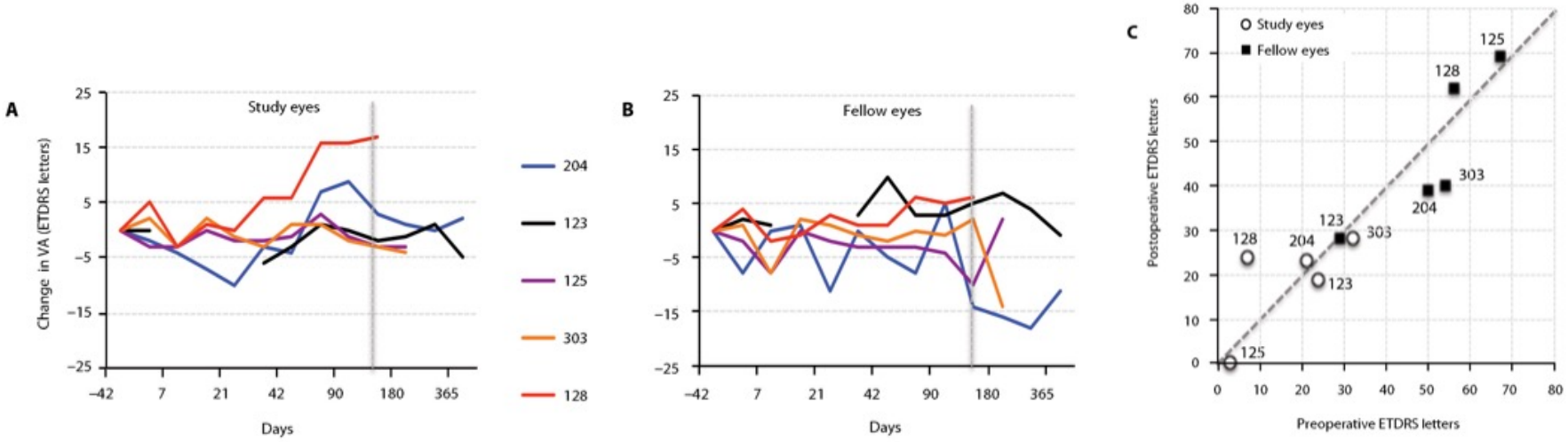

SCIENCE TRANSLATIONAL MEDICINE | RESEARCH ARTICLE

RETINAL DISEASE

A bioengineered retinal pigment epithelial monolay
for advanced, dry age-related macular degeneratio

Amir H. Kashani,[1]* Jane S. Lebkowski,[2] Firas M. Rahhal,[3] Robert L. Avery,[4] Hani Salehi-Had,[5] Wei
Chih-Min Lin,[6] Debbie Mitra,[1] Danhong Zhu,[7] Biju B. Thomas,[1] Sherry T. Hikita,[8] Britney O. Penni
Lincoln V. Johnson,[2,8] Dennis O. Clegg,[8] David R. Hinton,[1,7] Mark S. Humayun[1,9]*

CONCLUSIONS

4 of 5 subjects successfully received the composite implant

In all implanted subjects hESC-RPE and host photoreceptor integration was observed

One eye improved by 17 letters and two eyes demonstrated improved fixation

CPCB-RPE1 may improve visual function, at least in the short term

The NEW ENGLAND JOURNAL of MEDICINE

BRIEF REPORT

Autologous Induced Stem-Cell–Derived Retinal Cells for Macular Degeneration

M. Mandai, A. Watanabe, Y. Kurimoto, Y. Hirami, C. Morinaga, T. Daimon, M. Fujihara, H. Akimaru, N. Sakai, Y. Shibata, M. Terada, Y. Nomiya, S. Tanishima, M. Nakamura, H. Kamao, S. Sugita, A. Onishi, T. Ito, K. Fujita S. Kawamata, M.J. Go, C. Shinohara, K. Hata, M. Sawada, M. Yamamoto, S. Ol Y. Ohara, K. Yoshida, J. Kuwahara, Y. Kitano, N. Amano, M. Umekage, F. Kitao A. Tanaka, C. Okada, N. Takasu, S. Ogawa, S. Yamanaka, and M. Takahashi

iPSCs

A



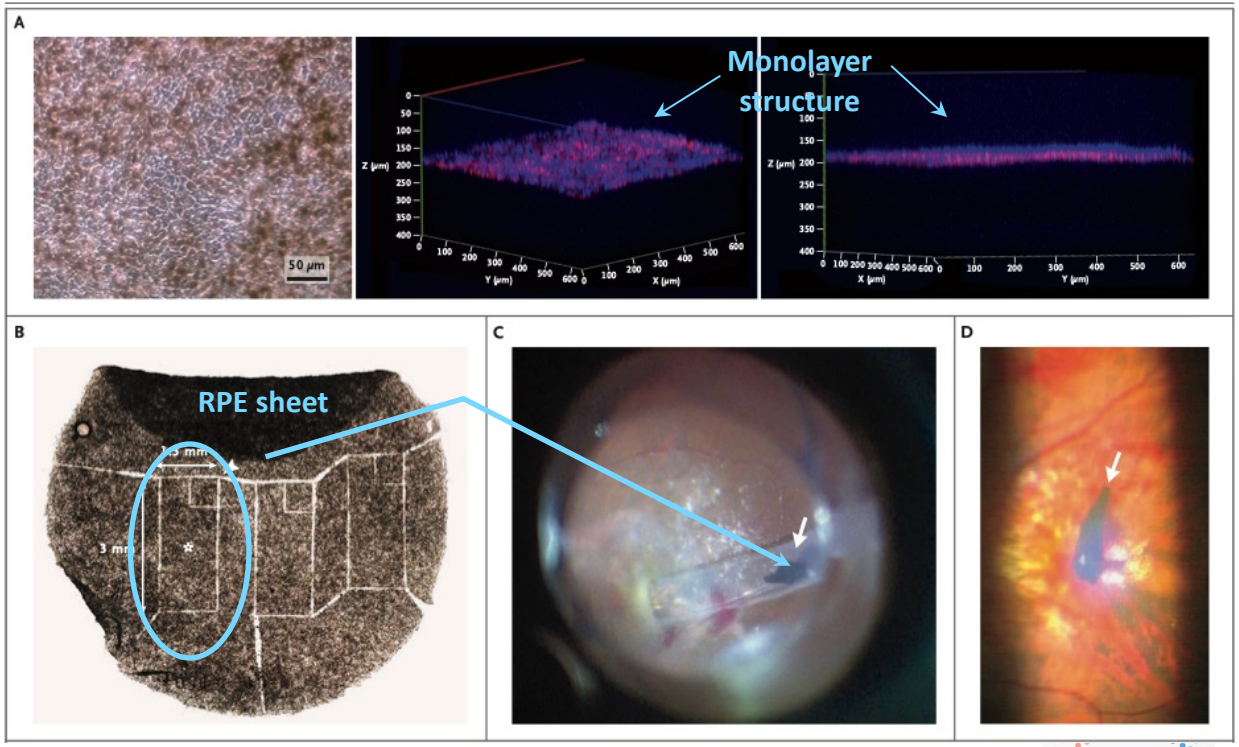

The NEW ENGLAND JOURNAL of MEDICINE

BRIEF REPORT

Autologous Induced Stem-Cell–Derived Retinal Cells for Macular Degeneration

M. Mandai, A. Watanabe, Y. Kurimoto, Y. Hirami, C. Morinaga, T. Daimon, M. Fujihara, H. Akimaru, N. Sakai, Y. Shibata, M. Terada, Y. Nomiya, S. Tanishima, M. Nakamura, H. Kamao, S. Sugita, A. Onishi, T. Ito, K. Fujita, S. Kawamata, M.J. Go, C. Shinohara, K. Hata, M. Sawada, M. Yamamoto, S. Ohta, Y. Ohara, K. Yoshida, J. Kuwahara, Y. Kitano, N. Amano, M. Umekage, F. Kitaoka, A. Tanaka, C. Okada, N. Takasu, S. Ogawa, S. Yamanaka, and M. Takahashi

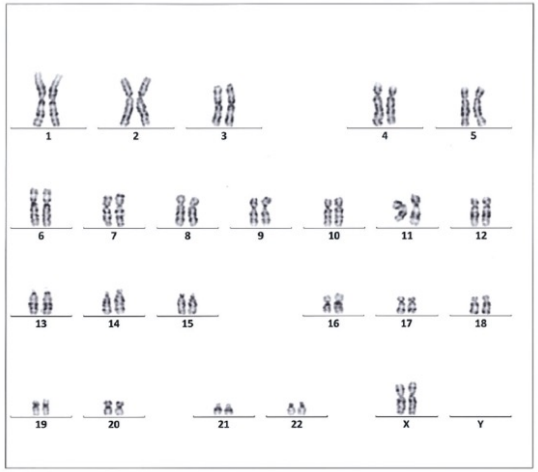

Characterization of RPE cells

Gene expression

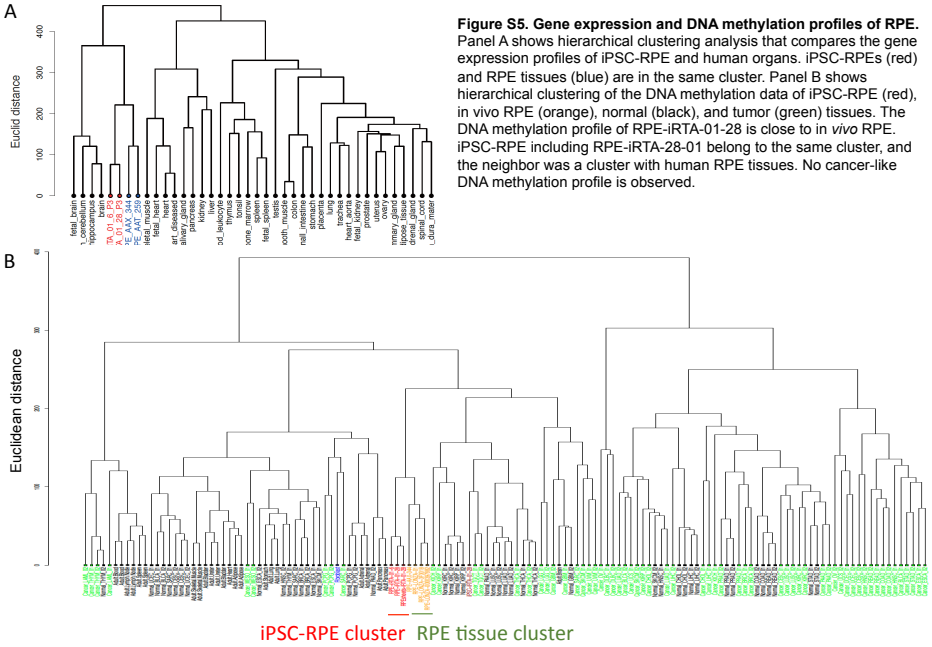

Figure S5. Gene expression and DNA methylation profiles of RPE. Panel A shows hierarchical clustering analysis that compares the gene expression profiles of iPSC-RPE and human organs. iPSC-RPEs (red) and RPE tissues (blue) are in the same cluster. Panel B shows hierarchical clustering of the DNA methylation data of iPSC-RPE (red), in vivo RPE (orange), normal (black), and tumor (green) tissues. The DNA methylation profile of RPE-iRTA-01-28 is close to in *vivo* RPE. iPSC-RPE including RPE-iRTA-28-01 belong to the same cluster, and the neighbor was a cluster with human RPE tissues. No cancer-like DNA methylation profile is observed.

DNA methylation


The NEW ENGLAND JOURNAL of MEDICINE

BRIEF REPORT

Autologous Induced Stem-Cell–Derived Retinal Cells for Macular Degeneration

M. Mandai, A. Watanabe, Y. Kurimoto, Y. Hirami, C. Morinaga, T. Daimon, M. Fujihara, H. Akimaru, N. Sakai, Y. Shibata, M. Terada, Y. Nomiya, S. Tanishima, M. Nakamura, H. Kamao, S. Sugita, A. Onishi, T. Ito, K. Fujita, S. Kawamata, M.J. Go, C. Shinohara, K. Hata, M. Sawada, M. Yamamoto, S. Ohta, Y. Ohara, K. Yoshida, J. Kuwahara, Y. Kitano, N. Amano, M. Umekage, F. Kitaoka, A. Tanaka, C. Okada, N. Takasu, S. Ogawa, S. Yamanaka, and M. Takahashi

Copy number alterations of Pt2 iPSCs and iPSC-RPE

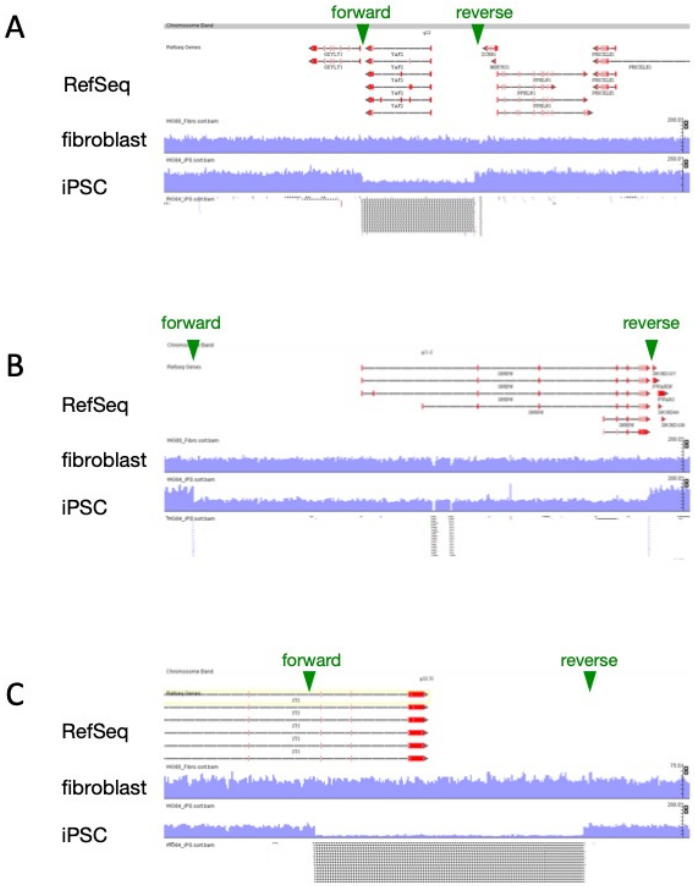

The NEW ENGLAND JOURNAL of MEDICINE

BRIEF REPORT

Autologous Induced Stem-Cell–Derived Retinal Cells for Macular Degeneration

M. Mandai, A. Watanabe, Y. Kurimoto, Y. Hirami, C. Morinaga, T. Daimon, M. Fujihara, H. Akimaru, N. Sakai, Y. Shibata, M. Terada, Y. Nomiya, S. Tanishima, M. Nakamura, H. Kamao, S. Sugita, A. Onishi, T. Ito, K. Fujita, S. Kawamata, M.J. Go, C. Shinohara, K. Hata, M. Sawada, M. Yamamoto, S. Ohta, Y. Ohara, K. Yoshida, J. Kuwahara, Y. Kitano, N. Amano, M. Umekage, F. Kitaoka, A. Tanaka, C. Okada, N. Takasu, S. Ogawa, S. Yamanaka, and M. Takahashi

CONCLUSIONS

At 1 year after surgery, the transplanted sheet remained intact.

No rejection! No use of immunosuppressive drug

Best corrected visual acuity (BCVA) had not improved or worsened

Macular edema was present

Clinical trials

AMD-GA 8

AMD-CMV 6

hESC-RPE 10

hiPSC-RPE 3

Subretinal suspension 8

Monolayer 6

Clinical Trial ID	Phase	Disease	No.	Cell Type	Cell Line	Differentiation Protocol	Delivery Method	Sponsor[s]	Refs.
NCT01344993 NCT02563782 NCT02463344	I/II	AMD-GA	9	hESC-RPE	MA-09	Spontaneous	Sub-retinal suspension	Ocata Therapeutics [Astellas]	[24, 25]
UMIN000011929	I	AMD-CNV	2	hiPSC-RPE	Autologous	Directed [42]	Monolayer	Riken Institute for Developmental Biology	[4]
On hold	I/II	AMD-CNV	2	hiPSC-RPE	Non-autologous	Directed [42]	Monolayer	Riken Institute for Developmental Biology	-
UMIN000026003	I	AMD-CNV	-	hiPSC-RPE	Allogeneic	Directed [42]	Monolayer	Kobe City Medical Centre General Hospital	-
NCT02590692	I/IIa	AMD-GA	5	hESC-RPE	CPCB	Spontaneous	Monolayer on substrate Paralyene C	Regenerative Patch Technologies	[3]
NCT01691261	I	AMD-CNV	2	hESC-RPE	SHEF-1.3	Spontaneous	Monolayer on substrate Polyethylene terephthalate	Pfizer	[2]
NCT01674829	I/II	AMD-GA	12	hESC-RPE	MA09	Spontaneous	Sub-retinal suspension	CHA Bio Biotech	[26]
NCT03305029	I	AMD-GA	3	hESC-RPE	SCNT-HESC	Spontaneous	Sub-retinal suspension	CHA University	-
NCT02286089	I/II	AMD-GA	24	hESC-RPE	HAD-C 102	Directed [9]	Sub-retinal suspension	BioTime CellCure Neurosciences	-
NCT02903576	I/II	AMD-GA AMD-CNV	18	hESC-RPE	MA09	Spontaneous	Sub-retinal suspension Monolayer on substrate	Federal University of Sao Paulo	-
NCT03046407	I/II	AMD-GA	10	hESC-RPE	Q-CTS-HESC-2	Spontaneous	Sub-retinal suspension	Chinese Academy of Sciences	-
NCT02755428	I/II	AMD-GA	10	hESC-RPE	Q-CTS-HESC-2	Spontaneous	Sub-retinal suspension	Chinese Academy of Sciences	-
NCT02749734	I/II	AMD-CNV	15	hESC-RPE	Q-CTS-HESC-2	Spontaneous	Sub-retinal suspension	Chinese Academy of Sciences	-

O'Neill et al. Current Stem Cell Research & Therapy, 2020

Like going to the Moon…

Vigtige overvejelser ved stamcelle terapi af AMD

- Produktion af tilstrækkeligt antal RPE celler af "Clinical- Grade" kvalitet
- Celle-transplantation ved brug af membran
- Immunsupprimerende medicin (hESC vs hiPSC)
- Lang-tids opfølgning (ift. cancer)

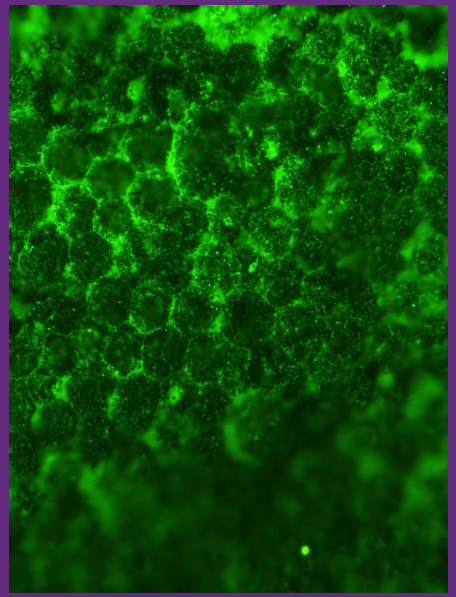

Hvordan kommer vi i mål med stamcelle terapi af AMD?

Produktion af nok RPE celler –“Clinical-Grade” kvalitet

Protokoller under udvikling (syntetiske, humane eller CG komponenter)

Celle-transplantation ved brug af membrane (sheet, PET, Parylene C, PLLA)

Bionedbrydelige membraner forøger chancen for donor-celle-integration/PR overlevelse

HLA-matched implantater (undgå immunsupprimerende medicin)

Patient-afledte celler (iPSC)

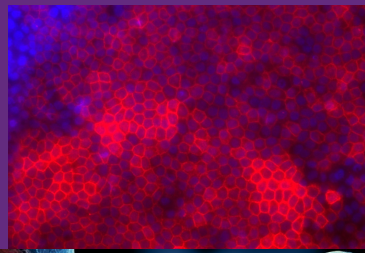

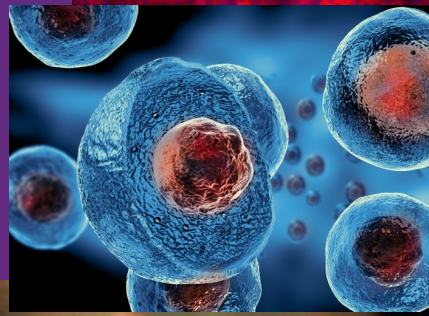

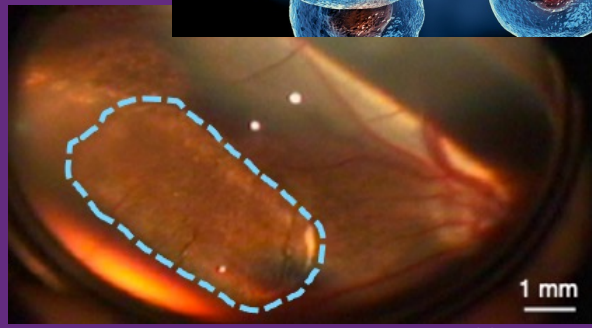

Hvordan kommer vi i mål med stamcelle terapi af AMD? FORTSAT

hESC-RPE: Benytter spontan differentiering (Ikke ønskværdigt ifm kommerciel brug)

Ny xeno-free procedure udviklet (indenfor 2 uger: 90% hESCs => RPE)

Opskalering?

Bevarelse af immunpriviligeret status

Transcleral OP virker sikker

Transplantion i “gammelt øje”

Kontrol af inflammation vigtig

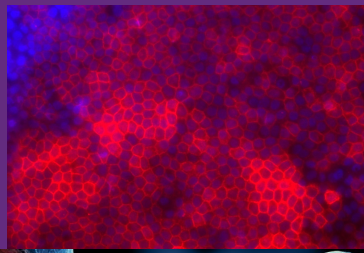

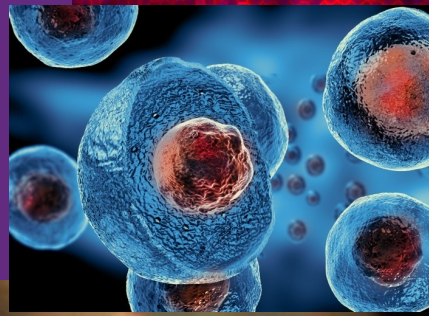

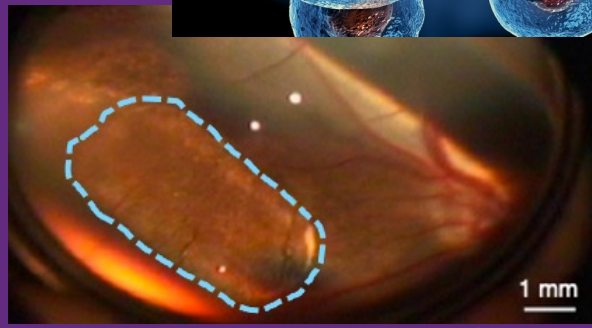

Tilvejebringelse:
Stamcelle-deriveret RPE celler “replacement” terapi

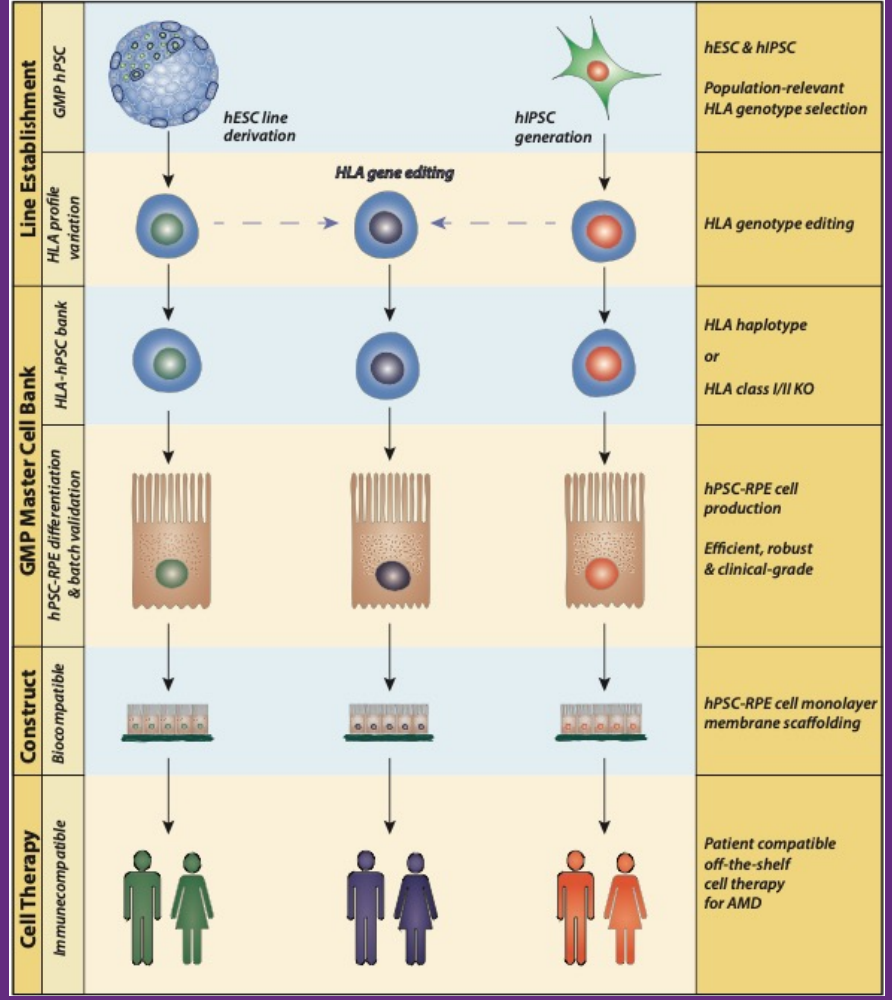

O’Neill et al. Current Stem Cell Research & Therapy, 2020

Outlook

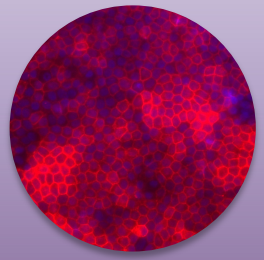

hESC-RPE

(+) Proof-of-concept

(–) Histocompatible transplantation

(?) Will hESC-RPE alter the natural history of the disease as the cells are zero years old, rather than the 60-plus years of the patients

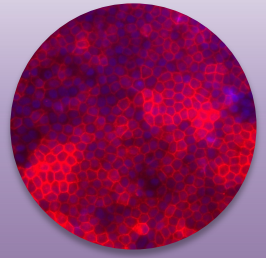

hiPSC-RPE

(+) Patient derived

(–) Reprogramming, differentiation, validation: Costly, Time

Bank of HLA-typed hESC-RPE and hiPSC-RPE cell lines

Konklusioner: RPE-stamcelle terapi af AMD

Kvalitet
Renhed
Funktionalitet
Overlevelse

Membran

OP teknik

Modulering af modtagervæv immun-status

"Commercial-scale-production"

STEM CELL THERAPY

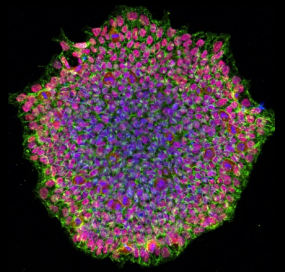

AARHUS UNIVERSITY